

Selective treatment of parasitism

Clinical indicators to monitor



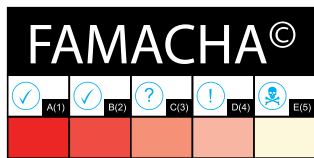
Refugia
Deworming
Monitoring
Pasture
Resistance
Resilience

In an integrated approach to managing parasites, the use of dewormers should be selective and targeted. It is important for farmers to be able to easily identify animals that need to be treated by monitoring simple clinical indicators.

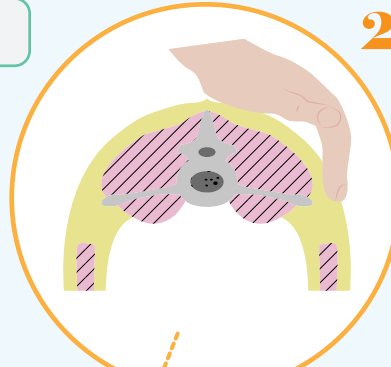
Clinical indicators to monitor

1. The colour of the conjunctiva (mucous membrane of the eyes)
2. The body condition, weight, and daily gain
3. The consistency of feces and cleanliness of hindquarters
4. Bottle jaw (submandibular oedema)

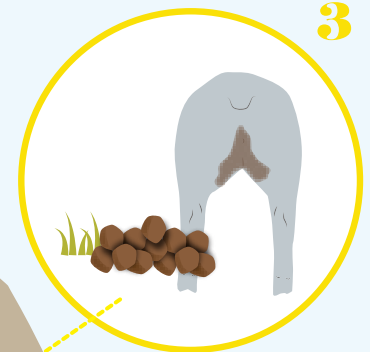
1



In weakened animals, gastrointestinal parasites can also lead to clinical manifestations of different diseases and therefore be associated with several other clinical signs.



2



3



4

Body condition / weight and daily gain / diminished general performance

- The body condition score of animals should be evaluated.
- The leanest animals could benefit from deworming.

The clinical indicators described above are not only associated with the presence of parasites. It may be important to consult a veterinarian for a more precise diagnosis.

Briefly, the following are several conditions whose clinical signs can be similar to those associated with gastrointestinal parasites: paratuberculosis, chronic diseases, coccidiosis, nutritional scours, anemia (of diverse causes), nutritional deficiencies, etc.

Consistency of feces and cleanliness of hindquarters

- Certain parasites can cause **diarrhea** or soft stool (notably *Teladorsagia* and *Trichostrongylus*).
- Diarrhea seen in grazing animals may justify deworming.
- Animals infested with a high level of parasites do not always have diarrhea.

CAUTION!

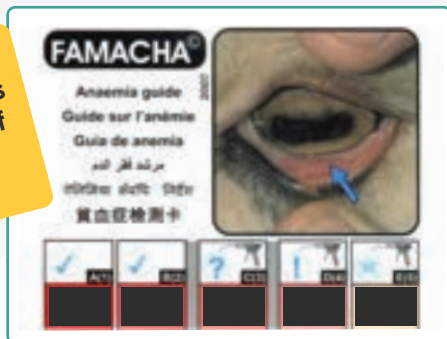Systematic treatment of all animals is no longer an accepted practice.



Colour of the conjunctiva with the FAMACHA® technique

- Tool that helps make decisions based on the detection of **anemia**, seen frequently during infestation with hemato-phage parasites such as *Haemonchus contortus*.
- To be performed when animals are put out to pasture, in July, when bringing animals back inside, and before any group deworming; also important during **at-risk periods**.

Major element of integrated strategies for management of gastrointestinal parasites



The **technique is simple**: all it takes is comparing **the colour of the conjunctiva** to a colorimetric chart developed for this purpose.

- Protect the eye with the upper eyelid, and use your thumb to apply pressure to the eyeball while pulling on the lower eyelid with the thumb of your other hand. The conjunctiva is then exposed. **ATTENTION**: do not inspect only the internal wall of the lower eyelid while pressing on the eyeball;
- The results are expressed on a scale of 1 to 5. **1** corresponds to a pink conjunctiva, while **5** means the conjunctiva is nearly white; do not use half-points (2.5 or 3.5, for example);
- The evaluation should be performed in a **well-lit area**, outdoors if possible;
- Ideally, **both eyes** of each animal are evaluated, and the highest score is used to determine if a treatment is required.

Consult a veterinarian for more info

Interpretation



For more information, visit www.cepoq.com/videos.php

A(1) B(2)

Animals **classed as 1 and 2** with the FAMACHA® chart **do not present clinical evidence of anemia**. It is not necessary to deworm these animals unless other clinical signs are present.

C(3)

Animals **classed as 3** with the FAMACHA® chart are **in a grey zone**; it is beneficial to deworm if:

- > 10% of the herd are classed as 4 or 5;
- It's the animals' first pasture season (usually recommended);
- The animals are pregnant or lactating females (usually recommended);
- The animals present poor body condition, weight loss, reduced daily gains, or any other clinical sign compatible with parasitism.




D(4) E(5)

Animals **classed as 4 and 5** with the FAMACHA® chart are **very anemic**: they should quickly be dewormed and re-evaluated. It is important to immediately consult your veterinarian if you have animals presenting this level of anemia.

Bottle jaw (submandibular oedema)

- Bottle jaw is a **swelling of the soft tissue** (oedema) under the jaw
- If an animal presents bottle jaw, it should be **dewormed**.
- Bottle jaw appears when certain parasites are present, such as *Haemonchus contortus* and *Teladorsagia circumcincta*.



It's important to confirm the presence of *Haemonchus* using laboratory tests, because this parasite is the most pathogenic in small ruminants. Your veterinarian can provide more information on the subject.

STOP

The tools presented above help determine which animals should be dewormed in the context of selective targeted treatment. As well as deworming animals that present one or more of the clinical indicators mentioned above, it may be beneficial to deworm ewes nursing three or more lambs, as well as lambs and ewe lambs during their first pasture season. This selective approach to deworming is a key element of integrated management strategies.

Sheet produced by:



Centre d'expertise en production ovine du Québec

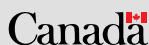
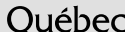
Project funded by:

Cultivons l'avenir 2

Une initiative fédérale-provinciale-territoriale

Agriculture, Pêcheries et Alimentation



Financial support for document translation provided by CSF



The strategies described in this pamphlet also largely apply to goats